

A comparative study of the blend sign and the black hole sign on CT as a predictor of hematoma expansion in spontaneous intracerebral hemorrhage

Ruili Li¹, Mingfei Yang^{2,*}

¹ Graduate School, Qinghai University, Xining, Qinghai, China;

² Department of Neurosurgery, Qinghai Provincial People's Hospital, Xining, Qinghai, China.

Summary

Hematoma expansion (HE) is a major determinant of a poor outcome in patients with a spontaneous intracerebral hemorrhage (sICH). The blend sign and the black hole sign are distinguished from non-contrast CT (NCCT) in patients with sICH, and both are independent neuroimaging predictors of HE. The purpose of the current study was to compare the value of the two signs in the prediction of HE. We retrospectively analyzed clinical and neuroimaging data from 228 patients with sICH who were treated at our hospital between August 2015 and September 2017. NCCT of the brain was performed upon admission (within 6 h of the onset of symptoms) to identify the blend sign and the black hole sign. HE was determined based on CT during a follow-up 24 h later. The sensitivity, specificity, positive predictive value (PPV), and negative predictive value (NPV) with which the blend sign and the black hole sign predicted HE were calculated. Receiver operating characteristic (ROC) curve analysis was performed in order to compare the accuracy of the two signs in predicting HE. The blend sign was identified in 46 patients (20.2%) and the black hole sign was identified in 38 (16.7%) based on NCCT of the brain upon admission. Of the 65 patients with HE, the blend sign was noted in 28 and the black hole sign was noted in 22. The blend sign had a sensitivity of predicting HE of 43.1%, a specificity of 89.0%, a PPV of 60.9%, and an NPV of 79.7%. In contrast, the black hole sign had a sensitivity of predicting HE of 33.9%, a specificity of 90.2%, a PPV of 57.9%, and an NPV of 77.4%. The area under the ROC curve was 0.660 for the blend sign and 0.620 for the black hole sign ($p = 0.516$). In conclusion, the blend sign and the black hole sign on CT are both good predictors of HE in patients with sICH, though the blend sign seems to have a higher level of accuracy.

Keywords: Intracerebral hemorrhage, hematoma expansion, CT, blend sign, black hole sign

1. Introduction

Spontaneous intracerebral hemorrhage (sICH) is a common and deadly neurological disorder with a high early mortality and poor prognosis; sICH accounts for approximately 15-30% of all strokes (1,2). About 30% of patients with sICH have hematoma expansion (HE), and HE is associated with a poor outcome in terms of neurological function (3).

Some predictors associated with HE have been identified in neuroimaging data from patients with sICH, and these predictors can help to identify patients at risk of HE and to improve clinical outcomes (4-6). HE occurs within the first 24 h of the onset of symptoms and is associated with fluid levels, heterogenous density, and irregular margins on computed tomography (CT) of the brain (7). Wada *et al.* identified a spot sign on computed tomography angiography (CTA) in patients with sICH, and they found that it was a prognostic factor related to HE (8). The spot sign on CTA is not only a predictor of HE in patients with sICH but also a reliable predictive factor for clinical prognosis and mortality (9). The spot sign

*Address correspondence to:

Dr. Mingfei Yang, Department of Neurosurgery, Qinghai Provincial People's Hospital, Xining 810007, Qinghai, China.
E-mail: 18678695779@163.com

is also related to persistent bleeding during evacuation of a hematoma, rebleeding, and a larger residual hematoma after surgery (10). Although the spot sign is a reliable predictor of HE and a poor outcome in patients with sICH, its accuracy is affected by many factors, such as the initial hematoma volume, a history of anticoagulant therapy, and the time from onset to CTA. Potential predictors in non-contrast CT (NCCT) need to be identified in the event CTA is not possible.

Several recent studies have noted a blend sign (4) or a black hole sign (5) on NCCT when patients with sICH are admitted, and these two novel signs have both proven to be neuroimaging predictors for HE. The blend sign is blending of the hypoattenuating region and the hyperattenuated region of a hematoma with a clear margin (4). The black hole sign is a relatively hypodense area within a hyperdense hematoma, with an obvious boundary adjacent to brain tissue (5). The blend sign and the black hole sign on NCCT are associated with the spot sign on CTA, and all three are predictive factors for a poor outcome in patients with sICH (11). However, no studies have compared the predictive value of the blend sign and the black hole sign on NCCT in the same cohort of patients with sICH. Thus, a retrospective cohort study was conducted to compare the value of the blend sign and the black hole sign in predicting HE.

2. Materials and Methods

2.1. Patient selection

Potential subjects were patients who were admitted to this Hospital between August 2015 and September 2017 and who had sICH as verified by an imaging study. This study was approved by the biomedical ethics committee of Qinghai Provincial People's Hospital, and its design met local ethical criteria for human research. Patients were included in this study if CT upon admission was performed within 6 hours of the onset of symptoms. NCCT of the brain was performed upon admission (within 6 h of the onset of symptoms) to identify the blend sign and the black hole sign. HE was determined based on subsequent CT during a follow-up 24 h later. Demographic characteristics, smoking status, alcohol consumption, the timing of CT, a history of hypertension and diabetes mellitus, and past medical history were recorded. The above information was collected by a blinded professional neurosurgeon.

The inclusion criteria were: *i*) age over 18 years; *ii*) sICH was verified with NCCT of the brain; *iii*) NCCT was performed upon admission (within 6 hours of the onset of symptoms); and *iv*) subsequent CT was performed during a follow-up 24 h later.

Exclusion criteria were: *i*) patients with ICH secondary to a condition such as trauma, a tumor, an aneurysm, an arteriovenous malformation (AVM), or

a hemorrhagic cerebral infarction, *ii*) patients who had received anticoagulant therapy, and *iii*) patients who underwent emergency evacuation of a hematoma prior to follow-up CT.

2.2. Imaging and detection of the blend sign and the black hole sign

CT scans were performed using standard clinical parameters with axial sections with a thickness of 5 mm. Two radiologists blinded to the clinical information independently reviewed CT images. In the event of a discrepancy, a consensus was reached through discussion.

The blend sign on NCCT meant that a hematoma with had well-defined components (a relatively hypoattenuated region and an adjacent hyperattenuated region). The blend sign indicated: *i*) a hematoma with a boundary between the hypoattenuated region and adjacent hyperattenuated region that was clearly visible to the naked eye; *ii*) the density of the two regions differed > 18 Hounsfield units (HU); and *iii*) the hypodense region of the hematoma was not completely encapsulated by the hyperdense region (4).

The black hole sign indicated: *i*) a hematoma with a hypoattenuated region and an adjacent hyperattenuated region; the relatively hypoattenuated region (black hole) had to have a distinct border; *ii*) the relatively hypoattenuated region was encapsulated within the hyperattenuating hematoma; and *iii*) the density of the two regions differed at least 28 HU (5).

2.3. Measurement of hematoma volume

The hematoma volume was calculated by using the ABC/2 formula. A was the largest diameter of the maximum hematoma level, B was the maximum diameter perpendicular to A, and C was the vertical depth of the hematoma. HE was defined as an increase in volume $> 33\%$ or an absolute increase of > 12.5 mL (12) during CT of the brain during follow-up 24 h later. Intraventricular hemorrhage is not included in the calculation of the cerebral parenchymal hematoma volume.

2.4. Statistical analysis

All statistical analysis was performed with the commercially available software SPSS version 21.0 (SPSS Inc. IBM, Armonk, NY). Continuous variables were analyzed using a *t*-test and their values are indicated as the mean \pm standard deviation (SD). Categorical variables were compared using a χ^2 test, and their values are indicated as a percentage or frequency distributions. Logistic regression analysis was performed to assess the association between clinical and radiological parameters and HE. Multivariate logistic

Table 1. Baseline characteristics of patients with HE and patients without HE [n (%)]

Items	Patients with HE (n = 65)	Patients without HE (n = 163)	χ^2/t	p
Mean age (yrs)	57 ± 11.5	59 ± 11.8	1.153	0.250
Sex, male	51 (78.5)	116 (71.2)	1.262	0.261
Hypertension	41 (63.1)	95 (58.3)	0.444	0.505
Diabetes mellitus	9 (13.8)	12 (9.8)	2.336	0.126
Smoking	24 (36.9)	45 (27.6)	1.911	0.167
Alcohol consumption	21 (32.3)	48 (29.4)	0.180	0.671
PLT (10 ⁹ /L)	136 ± 56	143 ± 55	0.863	0.389
Admission SBP (mmHg)	175 ± 29	168 ± 29	1.645	0.101
Admission DBP (mmHg)	107 ± 19	102 ± 20	1.728	0.085
Time to CT (h)	4.02 ± 1.36	4.52 ± 1.15	2.884	0.005
Baseline hematoma volume (mL)	31.05 ± 14.94	24.37 ± 17.14	2.751	0.006
Intraventricular hemorrhage	40 (61.5)	68 (41.7)	7.323	0.007
Blend sign	28 (43.1)	18 (11.0)	29.61	< 0.001
Black hole sign	22 (33.8)	16 (9.8)	19.32	< 0.001

Data are the mean ± SD or the number of patients. DBP, diastolic blood pressure; HE, hematoma expansion; PLT, platelet count; SBP, systolic blood pressure.

regression was used to analyze the odds ratio (OR) and 95% confidence interval (CI) of the blend sign and the black hole sign in predicting HE. The ability of the blend sign and the black hole sign to predict HE was analyzed using receiver-operator analysis. The area under the receiver operating characteristic curve (ROC) for the blend sign and the black hole sign was compared using a Z test. The interobserver reliability for detection of the blend sign and the black hole sign was confirmed by calculating k values. A P value < 0.05 was considered statistically significant.

3. Results

3.1. Baseline characteristics

A total of 228 patients met the inclusion criteria and all were enrolled in this study. Patients ranged in age from 26 to 79 years, and the mean age was 58.0 ± 11.7 years. A total of 61 patients (26.8%) were female, and 167 (73.2%) were male. The mean interval from the onset of ICH to CT upon admission was 4.38 ± 1.23 h, and the mean baseline volume of a hematoma was 26.27 ± 16.82 mL. A hematoma was located in the basal ganglia (140, 61.4%), cortical-subcortical areas (31, 13.6%), the thalamus (27, 11.8%), the cerebellum (16, 7%), or brain stem (14, 6.1%). Baseline characteristics for patients with HE and patients without HE are shown in Table 1.

3.2. Patients with HE with the blend sign or the black hole sign on CT

Of the 228 patients with sICH, 46 (20.2%) had the blend sign and 38 (16.7%) had the black hole sign on CT of the brain upon admission. Compared to patients without HE, a higher proportion of patients with HE had the blend sign or the black hole sign. Interobserver reliability was exceptional for the identification of the blend sign (k = 0.928) and the black hole sign

Table 2. Multivariate analysis of HE

Items	HE		
	OR	95% CI	p
Intraventricular hemorrhage	2.501	1.300-4.813	0.006
Blend sign	3.800	1.678-8.605	0.001
Black hole sign	2.726	1.097-6.777	0.031

HE, hematoma expansion.

(k = 0.915). Multivariate analysis indicated that intraventricular hemorrhage, the blend sign, and the black hole sign were associated with HE (Table 2).

Both the blend sign and the black hole sign were found in 26 patients, and 18 (69.2%) had HE. Of 20 patients with the blend sign but no black hole sign, 10 (50.0%) had HE. Of 12 patients with only the black hole sign, 4 (33.3%) had HE. A total of 170 patients had neither the blend sign nor the black hole sign, and only 34 (20.0%) had HE. The frequency of HE in patients with the blend sign and/or the black hole sign is shown in Figure 1.

3.3. The accuracy of the blend sign and the black hole sign in predicting HE

The blend sign had a sensitivity of predicting HE of 43.1%, a specificity of 89.0%, a positive predictive value (PPV) of 60.9%, and a negative predictive value (NPV) of 79.7%. The black hole sign had a sensitivity 33.9%, a specificity of 90.2%, a PPV of 57.9%, and an NPV of 77.4%. ROC curve analysis was used to compare the accuracy of the blend sign and the black hole sign in predicting HE, and the ROC curves for the two signs as predictors of HE in patients with sICH are shown in Figure 2. The area under the curve was 0.660 for the spot sign and 0.620 for the black hole sign. There were no significant differences in the area under ROC curves for the two signs (p = 0.516).

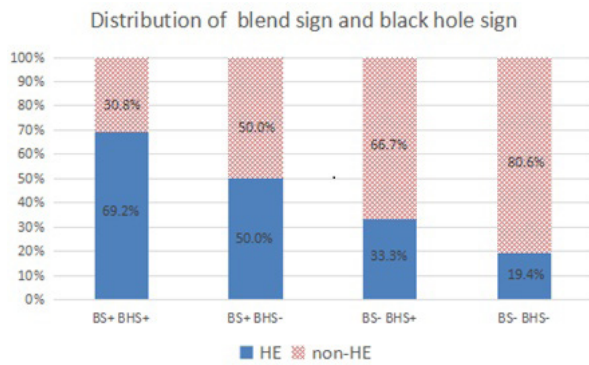


Figure 1. Frequency of a blend sign and a black hole sign in HE. BHS, black hole sign; BS, blend sign; HE, hematoma expansion. The proportion of BS+BHS+ is 69.2%, the proportion of BS+BHS- is 50.0%, the proportion of BS-BHS+ is 33.3%, and the proportion of BS-BHS- is 19.4%.

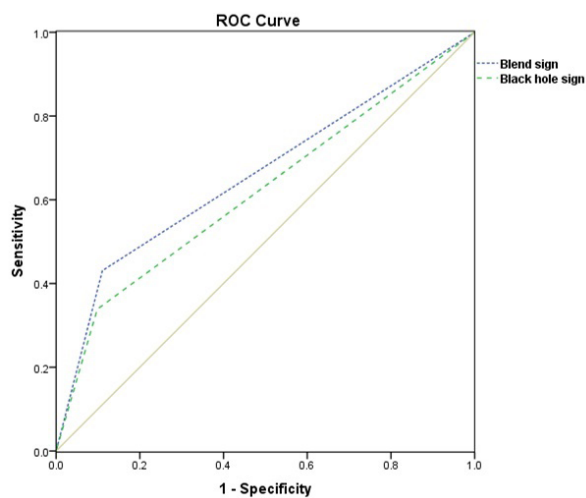


Figure 2. Receiver operating characteristic (ROC) curve as a result of classifying HE in binary terms. HE, hematoma expansion. The area under the curve was 0.660 for a blend sign and 0.620 for a black hole sign, $p = 0.516$.

4. Discussion

The current study is the first to compare the value of the blend sign and the black hole sign on NCCT in predicting HE in the same cohort of patients with sICH, and results indicated that the blend sign and the black hole sign are both good predictors of HE. Although the accuracy of prediction did not differ significantly, the blend sign seems to be better at predicting HE. Univariate analysis indicated that the time from the onset of symptoms to CT upon admission, baseline hematoma volume, and intraventricular hemorrhage were also associated with HE. Recent studies have indicated that the blend sign, the black hole sign, and the spot sign are all independent predictors of HE and that the spot sign has a higher level of predictive accuracy (13,14). Consistent with previous studies, the current study also found that both the blend sign and the black hole sign can effectively predict HE.

In patients with sICH, risk factors for HE include

primary hypertension, cerebral amyloid angiopathy, diabetes mellitus, and abnormal coagulation function. HE is significantly associated with neurological deterioration, a poor outcome in terms of function, and a high mortality (15,16). The pathogenesis of HE may be related to the heterogeneity of a hematoma. The heterogeneity of a hematoma's density on NCCT is associated with HE within the first 24 h of the onset of symptoms (7). The main difference between the blend sign and the black hole sign is the heterogeneity of a hematoma. Compared to the black hole sign, the blend sign is easier to identify. Li *et al.* proposed this new neuroimaging predictor, and they found that the blend sign had a sensitivity of predicting HE of 39.3%, a specificity of 95.5%, a PPV of 82.7%, and an NPV of 74.1% (4). In the current study, the blend sign had a high level of sensitivity and a higher NPV but a lower level of specificity and a lower PPV. The accuracy with which the blend sign can predict HE might be influenced by many potential factors. The mean time from the onset of symptoms to CT upon admission (4.02 h in patients with HE, 4.52 h in patients without HE) was greater than that in the study by Li *et al.* (1.67 h in patients with HE, 2.76 h in patients without HE). This difference may be related to the fact that patients lived in areas at higher altitudes, that patients had to travel further before admission, or the fact that care was less accessible. In addition, the baseline hematoma volume (31.05 mL in patients with HE, 24.37 mL in patients without HE) was greater than that in the study by Li *et al.* (24.31 mL in patients with HE, 13.12 mL in patients without HE). The difference in the time from the onset of symptoms to CT upon admission and the baseline hematoma volume may have influenced the predictive value of HE. Further studies are needed to identify the exact factors that affect the accuracy with which HE is predicted. Early detection of the blend sign helps to estimate prognosis and could serve as a potential therapeutic target (17). The blend sign on an initial CT scan is closely associated with postoperative hemorrhaging in patients with sICH who undergo stereotactic minimally invasive surgery (18). The blend sign on CT may be associated with the spot sign on CTA, and both can predict secondary neurological deterioration in patients with sICH (19).

In 2016, Boulouis *et al.* reported that the hypoattenuated region within the hematoma on NCCT could predict HE (20). However, previous studies did not provide standard imaging markers for the prediction of HE. Based on differences in the heterogeneity of a hematoma on NCCT, Li *et al.* identified the black hole sign and they confirmed that it is a novel predictor of HE in patients with sICH (5). The relationship between the black hole sign and the blend sign is still uncertain. The black hole sign was associated with the blend sign in the current study, and patients with both the blend sign and the black hole sign had a higher risk

of developing HE. The incidence of HE was higher in patients with the blend sign but not the black hole sign than in patients with only the black hole sign. The black hole sign is thought to reflect bleeding during different periods, and a recent hemorrhage appears as hypoattenuation on NCCT (5). After blood coagulated, serum was isolated and hyperattenuation was evident. The black hole sign seems to follow the same process as the blend sign. Li *et al.* found that the black hole sign had a sensitivity of predicting HE of 31.9%, a specificity of 94.1%, a PPV of 73.3%, and an NPV of 73.2% (5). In the current study, the black hole sign had a higher level of sensitivity and a higher NPV but a lower level of specificity and a lower PPV. Many factors may influence the predictive value of the black hole sign. In the current study, the mean time from the onset of symptoms to CT upon admission (4.02 h in patients with HE, 4.52 h in patients without HE) was greater than that in the study by Li *et al.* (2.3 h in patients with HE, 2.6 h in patients without HE). Furthermore, the average baseline hematoma volume also differed (31.05 mL in patients with HE, 24.37 mL in patients without HE) from that in the study by Li *et al.* (33.1 mL in patients with HE, 14.1 mL in patients without HE) (5). Further studies are needed to identify the exact factors affecting the predictive value of the black hole sign.

The current study had several limitations. This study was a single-center retrospective cohort study with a relatively small sample size. Only NCCT within 6 h of admission was examined, which may have led to a potential selection bias. The time from the onset of ICH to CT upon admission was relatively long, which may have affected the predictive accuracy of the blend sign and the black hole sign. In addition, this study only analyzed the blend sign and the black hole sign. A study with a larger sample size needs to be conducted in the future to compare the clinical value of comprehensive neuroimaging factors in patients with sICH.

In conclusion, the blend sign on NCCT in patients with sICH was associated with the black hole sign. Both have are accurate predictors of HE, and the blend sign appeared to have a greater predictive value. Patients with both the blend sign and the black hole sign have a higher risk of HE. Neuroimaging factors on NCCT are increasingly crucial to predicting HE when an immediate CTA is not possible. In the near future, a comprehensive scoring system should be devised to effectively predict HE and prognosis. This would benefit all patients with sICH.

Acknowledgements

This study was funded by grants from the Qinghai Province Health and Family Planning Commission (2016WJZDX13), and the Qinghai Province Natural Science Foundation (2015ZJ912).

References

1. Yang G, Shao GF. Elevated serum IL-11, TNF alpha, and VEGF expressions contribute to the pathophysiology of hypertensive intracerebral hemorrhage (HICH). *Neurol Sci.* 2016; 37:1253-1259.
2. Hemphill JC, Greenberg SM, Anderson CS, *et al.* Guidelines for the management of spontaneous intracerebral hemorrhage: A guideline for healthcare professionals from the American Heart Association/American Stroke Association. *Stroke.* 2015; 46:2032-2060.
3. Guan J, Hawryluk GW. Targeting secondary hematoma expansion in spontaneous intracerebral hemorrhage-state of the art. *Front Neurol.* 2016; 7:187.
4. Li Q, Zhang G, Huang YJ, Dong MX, Lv FJ, Wei X, Chen JJ, Zhang LJ, Qin XY, Xie P. Blend sign on computed tomography: Novel and reliable predictor for early hematoma growth in patients with intracerebral hemorrhage. *Stroke.* 2015; 46:2119-2123.
5. Li Q, Zhang G, Xiong X, Wang XC, Yang WS, Li KW, Wei X, Xie P. Black hole sign: Novel imaging marker that predicts hematoma growth in patients with intracerebral hemorrhage. *Stroke.* 2016; 47:1777-1781.
6. Orito K, Hirohata M, Nakamura Y, Takeshige N, Aoki T, Hattori G, Sakata K, Abe T, Uchiyama Y, Sakamoto T, Morioka M. Leakage sign for primary intracerebral hemorrhage: A novel predictor of hematoma growth. *Stroke.* 2016; 47:958-963.
7. Blacquiere D, Demchuk AM, Al-Hazzaa M, *et al.* Intracerebral hematoma morphologic appearance on noncontrast computed tomography predicts significant hematoma expansion. *Stroke.* 2015; 46:3111-3116.
8. Wada R, Aviv RI, Fox AJ, Sahlas DJ, Gladstone DJ, Tomlinson G, Symons SP. CT angiography "spot sign" predicts hematoma expansion in acute intracerebral hemorrhage. *Stroke.* 2007; 38:1257-1262.
9. Morotti A, Jessel MJ, Brouwers HB, Falcone GJ, Schwab K, Ayres AM, Vashkevich A, Anderson CD, Viswanathan A, Greenberg SM, Gurol ME, Romero JM, Rosand J, Goldstein JN. CT angiography spot sign, hematoma expansion, and outcome in primary pontine intracerebral hemorrhage. *Neurocrit Care.* 2016; 25:79-85.
10. Brouwers HB, Raffeld MR, van Nieuwenhuizen KM, *et al.* CT angiography spot sign in intracerebral hemorrhage predicts active bleeding during surgery. *Neurology.* 2014; 83:883-889.
11. Sporns PB, Schwake M, Kemmling A, Minnerup J, Schwindt W, Niederstadt T, Schmidt R, Hanning U. Comparison of spot sign, blend sign and black hole sign for outcome prediction in patients with intracerebral hemorrhage. *J Stroke.* 2017; 19:333-339.
12. Davis SM, Broderick J, Hennerici M, Brun NC, Diringer MN, Mayer SA, Begtrup K, Steiner T. Hematoma growth is a determinant of mortality and poor outcome after intracerebral Hemorrhage. *Neurology.* 2006; 66:1175-1181.
13. Zheng J, Yu Z, Xu Z, Li M, Wang X, Lin S, Li H, You C. The accuracy of the spot sign and the blend sign for predicting hematoma expansion in patients with spontaneous intracerebral hemorrhage. *Med Sci Monit.* 2017; 23:2250-2257.
14. Yu Z, Zheng J, Ma L, Guo R, Li M, Wang X, Lin S, Li H, You C. The predictive accuracy of the black hole sign

- and the spot sign for hematoma expansion in patients with spontaneous intracerebral hemorrhage. *Neurol Sci.* 2017; 38:1591-1597.
15. Dowlatshahi D, Demchuk AM, Flaherty ML, *et al.* Defining hematoma expansion in intracerebral hemorrhage: Relationship with patient outcomes. *Neurology.* 2011; 76:1238-1244.
 16. Delcourt C, Huang Y, Arima H, Chalmers J, Davis SM, Heeley EL, Wang J, Parsons MW, Liu G, Anderson CS. Hematoma growth and outcomes in intracerebral hemorrhage: The INTERACT 1 study. *Neurology.* 2012; 79:314-319.
 17. Li Q, Yang WS, Wang XC, Cao D, Zhu D, Lv FJ, Liu Y, Yuan L, Zhang G, Xiong X, Li R, Hu YX, Qin XY, Xie P. Blend sign predicts poor outcome in patients with intracerebral hemorrhage. *PLoS One.* 2017; 12:e0183082.
 18. Wu GF, Shen ZK, Wang LK, Sun S, Luo J, Mao Y. Post-operative re-bleeding in patients with hypertensive ICH is closely associated with the CT blend sign. *BMC Neurology.* 2017; 17:131.
 19. Sporns PB, Schwake M, Schmidt R, Kemmling A, Minnerup J, Schwindt W, Cnyrim C, Zoubi T, Heindel W, Niederstadt T, Hanning U. Computed tomographic blend sign is associated with computed tomographic angiography spot sign and predicts secondary neurological deterioration after intracerebral hemorrhage. *Stroke.* 2017; 48:131-135.
 20. Boulouis G, Morotti A, Brouwers HB, Charidimou A, Jessel MJ, Auriel E, Pontes-Neto O, Ayres A, Vashkevich A, Schwab KM, Rosand J, Viswanathan A, Gurol ME, Greenberg SM, Goldstein JN. Association between hypodensities detected by computed tomography and hematoma expansion in patients with intracerebral hemorrhage. *JAMA Neurology.* 2016; 73:961-968.

(Received November 14, 2017; Revised December 9, 2017; Accepted December 22, 2017)