

Difference in distribution of malignant melanoma and melanocytic nevus in the palm and finger

Mana Nishiguchi, Yuki Yamamoto*, Tomoyuki Hara, Hisako Okuhira, Yutaka Inaba, Kayo Kunimoto, Naoya Mikita, Chikako Kaminaka, Nobuo Kanazawa, Masatoshi Jinnin

Department of Dermatology, Wakayama Medical University Graduate School of Medicine, Wakayama, Japan.

Summary

We conducted a study to try to plot the lesions of melanocytic nevus and malignant melanoma on the palm and fingers, and compared them to identify the different distribution pattern of both lesions. Data on 8 patients with melanomas (4 male and 4 female) and 26 patients with melanocytic nevus (6 male and 20 female) of palm and finger pulp who visited Wakayama Medical University Hospital between 1986 and 2018 was retrospectively collected. We found that all of the 8 lesions of melanoma were located on the finger pulps and distal to the 'distal transverse crease' of the palm, and that melanomas were not present proximal to the transverse crease. On the other hand, melanocytic nevus was present in the proximal area to the distal transverse crease of the palm more frequently than melanomas (50.0% vs. 0%), and there was statistically significant difference ($p = 0.011$ by Fisher's exact probability test). From these observations, our findings may reveal the contribution of mechanical stress to the cause of palmar melanoma, and may facilitate clinical differentiation between malignant melanoma and melanocytic nevus by the localization. Further studies with increased number of patients are needed to validate the finding.

Keywords: Acral lentiginous melanoma, palmar melanoma, nevus cell nevus

It is important to investigate the causes, risk factors, or mechanism of tumorigenesis in malignant melanoma. Ultraviolet rays are clearly involved in the development of melanoma via the mutagenesis of BRAF or NRAS gene. However, melanoma also occurs in the unexposed area to ultraviolet rays including the palm and sole.

Acral lentiginous melanoma (ALM), lesions occurring on the extremities, was firstly defined by Reed (1). ALM is the most common form of melanoma in Japanese patients, and accounts for approximately 50% of all melanoma cases (2). Among ALM, the lesions on foot sole is most frequent, followed by the lower nail lesions (3).

On the other hand, the occurrence frequency of malignant melanoma in the palm is relatively low

(10%) (4), thus suggesting that cases with palmar ALM are rare, and that there may be different etiology between palmar melanoma and planter melanoma. Although characteristic genetic alterations are detected in melanomas according to their involved areas, BRAF or NRAS are not frequently found in ALM, and no previous studies have reported characteristic genetic alteration of palmar melanoma. Accordingly, we supposed that factors other than genetic abnormality were involved in the etiology of palmar ALM.

In addition, as far as we searched, there has been no report describing the predilection sites of melanocytic nevus. In general, Unna melanocytic nevus tends to occur in the trunk whereas Miescher nevus is known to be found in the face. In this study, we tried to plot the lesions of melanocytic nevus and malignant melanoma on the palm and fingers, and compared them to identify the different distribution pattern.

We retrospectively collected data on 8 patients with melanomas (4 male and 4 female; 2 patients in the palm and 6 patients in the finger pulp) and 26 patients with melanocytic nevus (6 male and 20 female; 16

*Address correspondence to:

Dr. Yuki Yamamoto, Department of Dermatology, Wakayama Medical University Graduate School of Medicine, 811-1 Kimiidera, Wakayama, Wakayama 641-0012, Japan.
E-mail: yuki@wakayama-med.ac.jp

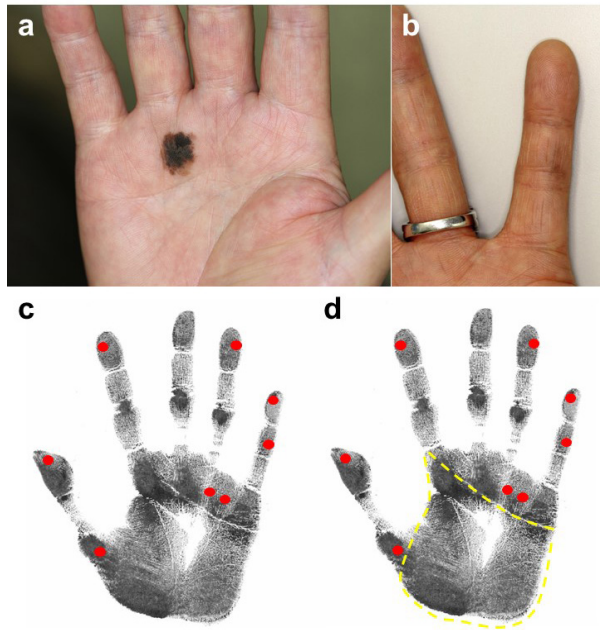


Figure 1. Distribution of melanoma on the palm and fingers. (a and b) Representative clinical images of patients with melanoma on the palm (a: 64 year-old male) and finger pulp (b: 59-year-old female). (c and d) The center of each lesion of 8 melanoma is plotted in red. In (d), proximal to the distal transverse crease of the palm was surrounded by yellow dotted line.

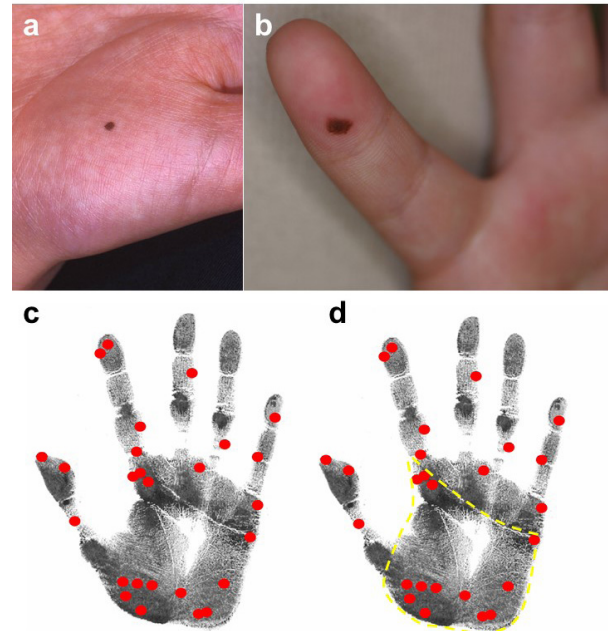


Figure 2. Distribution of nevus on the palm and fingers. (a and b) Representative clinical images of patients with nevus on the palm (a: 9 year-old male) and finger pulp (b: 5 year-old female). (c and d) The center of each lesion of 26 nevus is plotted in red. In (d), proximal to the distal transverse crease of the palm was surrounded by yellow dotted line.

patients in the palm and 10 patients in the finger pulp) of palm and finger pulp who visited Wakayama Medical University Hospital between 1986 and 2018. Lesions that developed primarily in the subungual, periungual and dorsum areas of hand were excluded from the analysis. All patients were diagnosed based on clinical manifestation, clinical course, and/or dermoscopic findings. Furthermore, the diagnosis was histopathologically confirmed in all patients with melanomas and 6 of 26 patients with melanocytic nevus. We then adjusted the size of the palm and fingers in each clinical image by means of digital magnification according to the previous study (5), and plotted the center of each lesion.

Among the six melanoma lesions of fingers, two were present on 1st fingers, one on 2nd fingers, one on 4th fingers, and two on 5th fingers. Representative clinical images of patients with melanoma of palm and finger pulp were shown in Figure 1a and 1b, respectively, and there were no significant differences in sex, gender and histopathological features between them. However, we found that all of the 8 lesions of melanoma were located on the finger pulps and distal to the 'distal transverse crease' of the palm (Figure 1c), and that melanomas were not present proximal to the distal transverse crease (surrounded by yellow dotted line in Figure 1d).

On the other hand, there were three nevus lesions on 1st fingers, three on 2nd fingers, and one on 3th

fingers, one on 4th fingers, and two on 5th fingers, thus indicating that both melanoma and melanocytic nevus showed a tendency to be present on 1st and 5th finger. As shown in Figure 2a and 2b as representative clinical images of patient with nevus of palm and finger pulp, respectively, there were no significant differences in sex, gender and histopathological features between them. Unlike melanomas, however, we found that 13 melanocytic nevus were present (Figure 2c) proximal to the distal transverse crease of the palm (surrounded by yellow dotted line in Figure 2d).

We then compared the frequencies of melanoma and melanocytic nevus between in the proximal area of the distal transverse crease of the palm and in remaining parts of palm and fingers. As a result, we found that melanocytic nevus were present in the proximal area to the distal transverse crease of the palm more frequently than melanomas (50.0% vs. 0%), and there was statistically significant difference ($p = 0.011$ by Fisher's exact probability test). Therefore, our results suggest that the distribution of melanoma is different from that of melanocytic nevus in the palm and finger pulp.

ALM in the sole is known to be mostly found in the heel, followed by in the big toe. On the other hand, Minagawa et al. reported that the frequency of melanoma in the rear and front of the foot was extremely high compared to the arch area (5). The authors concluded that there may be more mechanical

stress such as plantar pressure and shear stress in the rear and front of the foot, which results in the increased susceptibility for melanomas.

Our finding that ALM tends to occur in the finger pulp and distal area of the distal transverse crease of the palm may indicate that mechanical stress also induces the formation of palmar melanoma: Blisters and calluses are often induced by mechanical stress on the hand: Actually, they are usually seen in the finger pulps and palm distal to the 'distal transverse crease', but rarely in the proximal area of the palm. Consistently, lower occurrence frequency of ALM in the palm can be explained by the minor mechanical stress compared to that in the sole.

Taken together, our findings may reveal the contribution of mechanical stress to the cause of palmar ALM, and may facilitate clinical differentiation between malignant melanoma and melanocytic nevus by the localization. Further studies with increased

number of patients are needed to validate the finding.

References

1. Li H, Liu X. Acral lentiginous melanoma. *Clinics in Oncology*. 2018; 3:1-10.
2. Kato T, Kumasaka N, Suetake T, Tabata N, Tagami H. Clinicopathological study of acral melanoma in situ in 44 Japanese patients. *Dermatology*. 1996; 193:192-197.
3. Lv J, Dai B, Kong Y, Shen X, Kong J. Acral melanoma in Chinese: A clinicopathological and prognostic study of 142 cases. *Sci Rep*. 2016; 6: 31432.
4. Feibleman CE, Stoll H, Maize JC. Melanomas of the palm, sole, and nailbed: A clinicopathologic study. *Cancer*. 1980; 46:2492-2504.
5. Minagawa A, Omodaka T, Okuyama R. Melanomas and mechanical stress points on the plantar surface of the foot. *N Engl J Med*. 2016; 374:2404-2406.

(Received August 4, 2019; Revised August 22, 2019; Accepted August 26, 2019)