

Clinical characteristics of solitary intrahepatic biliary cyst

Zhipeng Sun^{1,§}, Bing Liu^{2,§}, Bin Shu¹, Xin Huang¹, Liang Wang¹, Shizhong Yang^{1,*}

¹ Hepatopancreatobiliary Center, Beijing Tsinghua Changgung Hospital, School of Clinical Medicine, Institute for Precision Medicine, Tsinghua University, Beijing, China;

² Hepato-Pancreato-Biliary Surgery, The First Medical Center, Chinese PLA General Hospital, Beijing, China.

SUMMARY Solitary intrahepatic biliary cyst (SIBC) is a rare disease, and due to the lack of adequate understanding of it, SIBC is often misdiagnosed as simple liver cyst (SLC), which in turn affects the therapeutic effect. In order to arouse more attention to SIBC, combined with clinical experience in our center, this study specifically screened 3 representative cases of SIBC, and conducted a comprehensive retrospective analysis of their clinical characteristics, diagnosis and treatment process. Combined with the relevant literature, the diagnosis and treatment process of SIBC is widely discussed.

Keywords solitary intrahepatic biliary cyst, simple hepatic cyst, hepatic cyst, hepatectomy

Congenital hepatic cysts are relatively rare liver lesions that can be divided into simple hepatic cysts (SLC) and solitary intrahepatic biliary cysts (SIBC) depending on whether the cyst communicates with the bile duct (1,2). SIBC is a special type of biliary dilatation. Although congenital hepatic cysts are considered a congenital disease, most patients remain asymptomatic for many years and are occasionally detected during physical examinations in adulthood. Only a very small number of patients present with corresponding clinical symptoms in infancy and are diagnosed (3).

As a rare type of congenital hepatic cysts, SIBC is often misdiagnosed as SLC because it has not attracted enough concern and attention, which in turn affects the therapeutic effect and the prognosis of patients. In view of this, the authors selected 3 representative cases from SIBC patients diagnosed and treated in our center, and systematically summarized and analyzed their clinical characteristics as well as diagnosis and treatment process (Table 1).

Case 1: A 30-year-old female patient was admitted due to intermittent abdominal pain and discomfort for 3 months. The patient was admitted on June 5, 2017. The patient was diagnosed with "hepatic cyst, duodenal ulcer and pyloric obstruction" 16 months ago, and underwent "fenestrated jejunostomy and internal drainage of hepatic cyst, distal gastrectomy and Roux-en-Y gastrojejunostomy" in a local hospital. The patient had repeated nausea and vomiting after surgery. She was admitted to our department for further treatment. Contrast-enhanced MR of the upper abdomen

revealed "biliary cyst involving S4, S5, S8 after biliary cyst surgery and subtotal gastrectomy" (Figure 1 A, 1B). Middle lobectomy was considered. During the surgery, biliary dilatation in the right anterior lobe and middle liver was observed. Middle lobectomy and choledochocystectomy + intraoperative biliary T-tube drainage + intraoperative hilar cholangioplasty + choledochojejunostomy were performed. The surgical specimen was shown in Figure 2A. Postoperative pathology revealed biliary dilatation with biliary cyst formation. After discharge, the patient was followed up regularly at the 25th month, MRCP was performed during the follow-up (Figure 3A, 3B, 3C), no recurrence or complication occurred.

Case 2: A 70-year-old male patient was admitted to our hospital due to jaundice and icteric sclera for 20 days. The patient was admitted on April 16, 2017. One year ago, the patient developed jaundice with abdominal pain without obvious inducement. Abdominal MRI showed hilar cyst with biliary compression, mild intrahepatic biliary dilatation, gallbladder atrophy, and Chilaiditi syndrome. Resection of hilar biliary cyst, gallbladder extirpation and hepaticojejunostomy were performed in a local hospital, and a 4.0*3.5 cm cyst was palpable in hilar region during the surgery. Half a month after surgery, the patient started having intermittent high fever with nausea and vomiting. MRCP/CT in our hospital showed (Figure 1C, 1D): mild intrahepatic biliary dilatation and possible compensatory changes. In our hospital, left hemihepatectomy + resection of residual biliary cyst + choledochojejunostomy of the right hepatic

Table 1. General information of patients

No.	Gender	Major symptoms	Imaging	Location of biliary cyst	Cyst diameter (cm)	History of surgery at lesion site	Follow-up time (months)	Prognosis
1	Female	Abdominal pain	US/CT/MRCP	Porta hepatis	8.5	3	25	NDNR
2	Male	Abdominal pain	US/MRCP	Porta hepatis	2.8	1	33	NDNR
3	Female	Hyperpyrexia/jaundice	US/CT/MRCP	Porta hepatis	5.0	0	19	NDNR

US: ultrasonography; CT: Computer Tomography; MRCP: Magnetic Resonance Cholangiopancreatography; NDNR, No discomfort/no recurrence.

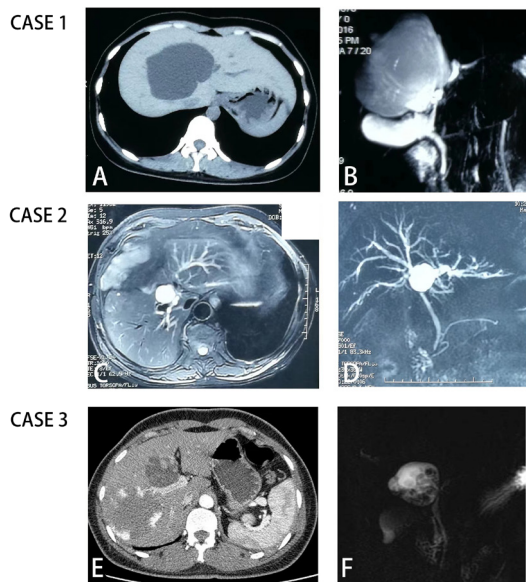


Figure 1. Imaging findings of the 3 cases of solitary intrahepatic biliary cyst. Case 1, abdominal CT (A) showed after biliary cyst surgery+subtotal gastrectomy, cyst lesion recurrent in the right liver lobe; MRCP (B) revealed single cystic lesion in the hilum, involving the left medial lobe and right anterior lobe. Case 2, MRCP (C, D) revealed after resection of biliary cyst+cholecystectomy+choledochojunctionostomy, intrahepatic biliary dilatation recurrent. Case 3, abdominal CT (E) showed cavernous hemangioma in the right liver lobe and biliary cyst in the left liver lobe. MRCP (F) showed biliary cyst in the left liver lobe, and large possibility of cavernous hemangioma in the right liver lobe.

duct was performed. The resected specimen is shown in Figure 2B. The patient was discharged safely on Day 6 after surgery. After discharge, the patient was followed up regularly for 33 months, MRCP was performed at the follow-up of the 33rd month (Figure 3D, 3E, 3F). No discomfort or complication occurred. Postoperative pathology revealed biliary dilatation with biliary cyst formation.

Case 3: A 33-year-old female patient was admitted due to intermittent right upper abdominal pain for 10 months. The enhanced CT of the upper abdomen revealed (Figure 1E, 1F): biliary cyst in the left liver lobe complicated with stones. The cyst was located in the left hepatic duct, and the surgical approach was tentatively left hemihepatectomy. During the surgery, dissection of the hilar bile duct showed that the hilar cyst originated from the common hepatic duct and showed a diverticular pattern. It measured about 5 × 5 × 4 cm and closely adhered to the left medial lobe of the liver and

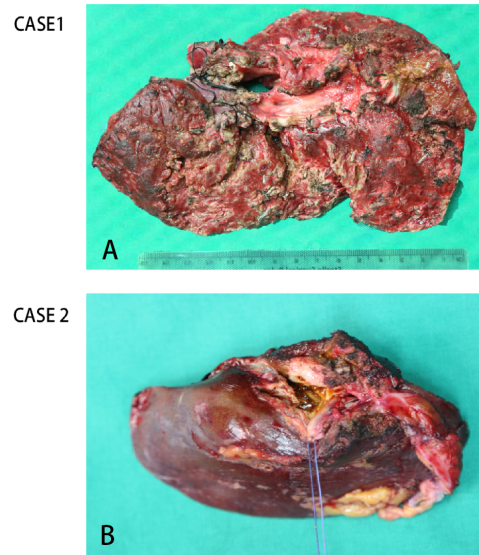


Figure 2. Surgically resected specimens: Case 1 was showed in (A), while case 2 was in (B). Both pathology result were biliary dilatation with biliary cyst formation.

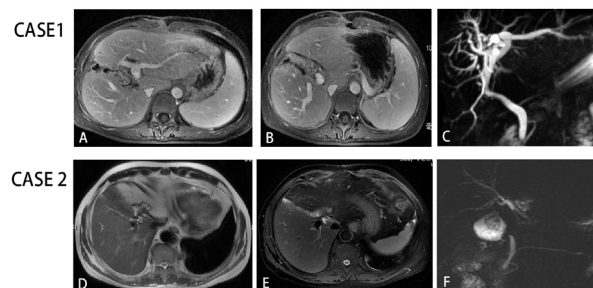


Figure 3. Imaging findings of postoperative reexamination. Case 1, MRCP findings (A, B, C) at 25th months after surgery, consistent with s/p partial hepatectomy, and no new abnormal dilated bile ducts were observed. Case 2, upper abdominal MRCP findings (D, E, F) 33rd months after surgery, consistent with s/p left hemihepatectomy, and no new abnormal dilated bile ducts were observed.

gallbladder. After incision from the bottom of the cyst, dark bile outflow was observed. Multiple stones were observed in the cyst, with the larger one about 1.5 cm in diameter, and cauliflower-like tissue was observed in the cyst wall. Specimens were taken during the surgery for pathology. Pathology (frozen): (intracystic polypoid mass) papillary cystadenoma with malignant changes. The patient was diagnosed with congenital biliary dilatation (type V) with cyst carcinogenesis and intracystic stones. Finally, cholecystectomy,

choledochal cyst resection, and hepatoduodenal lymph node dissection were performed. The surgery was successful, and the patient recovered well after surgery and was discharged safely on Day 8 after surgery. The patient was followed up regularly for 19 months after surgery. No discomfort or complication occurred and no tumor recurrence occurred. Postoperative pathology: Biliary cyst (common hepatic duct), with multiple well-differentiated papillary adenocarcinomas.

Biliary dilatation can occur in the intrahepatic and extrahepatic bile ducts and has a variety of different morphological manifestations, generally with choledochal cysts being the most common. The most widely used classification method is the protocol proposed by Todani et al. in 1977 (4). According to their classification, biliary dilatation is mainly divided into five types. Among them, Caroli disease is currently the only type identified to have a genetic background, which is caused by mutations in the PKHD1 gene and belongs to autosomal recessive diseases (5). According to this classification, all the three cases of biliary dilatation in this study can be classified as special Todani type V. According to Dong's classification proposed by Jiahong Dong et al in 2017 (6), the three cases of biliary dilatation in this study can be classified as special Dong type B1. but solitary intrahepatic biliary cyst are more accurate. Obstructive jaundice occurs when there is marked dilatation and bile retention at the lesion site, and complications occur. Among them, the common complications are: stones, cholangitis, acute pancreatitis, malignant tumors, portal hypertension, and chronic pancreatitis (7).

Since the findings on CT/MRI are very similar, biliary dilatation is often misdiagnosed as SLC (8), which has a huge impact on the choice of treatment options for this disease as well as therapeutic effect. In differentiating these two diseases, the most important is to determine whether cystic lesions communicate with the biliary system of the liver. In addition to routine examinations such as CT/MRI, ERCP is more helpful in judging whether cystic lesions communicate with the biliary system, thus helping to differentiate SLC from biliary dilatation (7). At the same time, dilated gallbladder diseases also need to be differentiated from intrahepatic and extrahepatic bile duct stones, cholangitis, hepatic hemangioma, primary liver cancer and other liver diseases. Differential diagnosis can be made according to the clinical manifestations of various diseases and typical imaging features.

In this study, Case 1 suggested that the first preoperative diagnosis has a great impact on the choice of surgical approaches, which may be the main cause of serious complications soon after surgery and also leads to the passive condition of the second surgery, and quality of life of the patients after surgery is seriously affected. As a result, the patient experienced obvious biliary dilatation again within 2 years after surgery, accompanied

by obvious discomfort, and had to undergo another larger surgery. Fortunately, the disease was completely cured after the surgery, and no discomfort and complication occurred during the follow-up at 2 years after surgery.

Case 2 also had a history of surgery at another hospital. Dilated bile duct not completely removed was the main reason of poor prognosis. According to the Guideline for congenital biliary dilatation issued in Japan in 2017 (9), there is no consensus on the extent of resection for this type of lesion. According to Chinese guidelines (10), cholecystectomy, resection of the affected hepatic segment, choledochectomy + choledochojejunostomy for extrahepatic lesions are recommended for type V, if the lesion invades the central hepatic duct at grade 3 and above. At the same time, according to previous studies by the author's team, a more aggressive surgical treatment is recommended for patients with type V biliary dilatation (11), and the extent of lesion resection needs to be extended to the distal normal bile duct. In terms of stone clearance rate, with or without postoperative discomforts, long-term cancer rate and other aspects, patients may benefit more. This case suggests that in the management of type V biliary dilatation, the extent of lesion involvement in patients should be fully assessed and the most appropriate surgical approach should be selected. This is important for the treatment outcome, as well as for the prevention and control of postoperative complications.

It has been shown that although biliary dilatation is a benign lesion, accounting for approximately 1% of benign biliary diseases (12), it increases the probability of malignant transformation at the lesion site, with higher rates of malignant transformation in types I, IV, and V. At the same time, the rate of malignant transformation increases further with age (13). The data showed that the probability of malignant transformation in patients with biliary dilatation was less than 1% before the age of 10 years and increased to 6.8% between 10 and 20 years, which further increased to 14.3% after the age of 20 years (14). The age of the highest incidence of complicated biliary malignancies is 32 years, which is 20 years earlier than normal people without biliary dilation (15). In Case 3 of this study, papillary adenocarcinoma associated with dilated cyst wall resulted in a poor prognosis (16), so early diagnosis as well as surgical intervention are very important for the treatment outcome as well as long-term prognosis of patients (15). At the same time, the age of the patient in case 3 was 33 years, which was consistent with the high incidence age group reported in the literature, suggesting that we should pay more attention to whether it is associated with malignant lesions and do a good job in surgical planning when diagnosing and treating patients with biliary dilatation in this age group. It is worth noting that in case 3, despite strict collection of medical history, adequate auxiliary examinations, including contrast-enhanced abdominal CT, MRI and other imaging examinations, biochemistry tests such as

tumor markers, were performed. However, we still failed to identify malignant lesions at the site of cystic dilatation before surgery. This suggests that although the malignant lesion rate of biliary dilatation is rare, we should still be fully prepared when performing the surgical plan, which is very important for the standardized treatment of biliary dilatation with malignant lesions.

As far as we know, although there have been previous case reports of SIBC (17,18), including cases of SIBC in infants (13,19), our series of SIBC cases reported this time are more comprehensive and representative, including multiple surgeries after initial misdiagnosis, the occurrence and treatment of surgical complications, the first diagnosis combined with carcinogenesis, and surgical approach adjustment after accidental detection of malignant lesions during surgery, which is the first comprehensive series of cases and comprehensive analysis of SIBC reports so far. Accordingly, we suggest that SIBC should be considered in the differential diagnosis of patients with solitary cystic mass at the hilum. Aggressive surgical treatment is also recommended in order to achieve radical results.

Funding: This work was supported by National Natural Science Foundation of China (grant number: 82090052); CAMS Innovation Fund for Medical Sciences (grant number: 2019-I2M-5-056); Tsinghua University Initiative Scientific Research Program of Precision Medicine (grant number: 2022ZLA007).

Conflict of Interest: The authors have no conflicts of interest to disclose.

References

- Brown DK, Kimura K, Sato Y, Pringle KC, Abu-Yousef MM, Soper RT. Solitary intrahepatic biliary cyst: diagnostic and therapeutic strategy. *J Pediatr Surg.* 1990; 25:1248-1249.
- Klein L, Meurisse N, Honore P, De Roover A, Detry O. Diagnosis and management of liver cysts. *Rev Med Liege* 2021; 76: 661-665. (in French)
- Bhosale M, Singh D. Giant congenital solitary nonparasitic cyst of the liver causing respiratory distress in a neonate. *J Indian Assoc Pediatr Surg.* 2016; 21: 72-74.
- Todani T, Watanabe Y, Narusue M, Tabuchi K, Okajima K. Congenital bile duct cysts: Classification, operative procedures, and review of thirty-seven cases including cancer arising from choledochal cyst. *Am J Surg.* 1977; 134: 263-269.
- Yonem O, Bayraktar Y. Clinical characteristics of Caroli's syndrome. *World J Gastroenterol.* 2007; 13: 1934-1937.
- Biliary Surgery Branch of Surgery Chinese Medical Association. Guideline for the diagnosis and treatment for biliary dilatation (2017 edition). *Chin J Dig Surg.* 2017; 16: 767-774.
- Saluja SS, Nayeem M, Sharma BC, Bora G, Mishra PK. Management of choledochal cysts and their complications. *Am Surg.* 2012; 78: 284-290.
- Du CX, Lu CG, Li W, Tang WB. Congenital hepatic cyst: Eleven case reports. *World J Clin Cases.* 2022; 10:9112-9120.
- Ishibashi H, Shimada M, Kamisawa T, Fujii H, Hamada Y, Kubota M, Urushihara N, Endo I, Nio M, Taguchi T, Ando H, Japanese Study Group on Congenital Biliary D. Japanese clinical practice guidelines for congenital biliary dilatation. *J Hepatobiliary Pancreat Sci.* 2017; 24:1-16.
- Hu B, Sun B, Cai Q, Wong Lau JY, Ma S, Itoi T, Moon JH, Yasuda I, Zhang X, Wang HP, Ryozaawa S, Rerknimitr R, Li W, Kutsumi H, Lakhtakia S, Shiomi H, Ji M, Li X, Qian D, Yang Z, Zheng X. Asia-Pacific consensus guidelines for endoscopic management of benign biliary strictures. *Gastrointest Endosc.* 2017; 86:44-58.
- Dong JH, Yang SZ, Xia HT, Duan WD, Ji WB, Gu WQ, Liang B, Huang ZQ. Aggressive hepatectomy for the curative treatment of bilobar involvement of type IV-A bile duct cyst. *Ann Surg.* 2013; 258:122-128.
- Jablonska B. Biliary cysts: etiology, diagnosis and management. *World J Gastroenterol.* 2012; 18:4801-4810.
- Clifton MS, Goldstein RB, Slavotinek A, Norton ME, Lee H, Farrell J, Nobuhara KK. Prenatal diagnosis of familial type I choledochal cyst. *Pediatrics.* 2006; 117:e596-600.
- Voyles CR, Smadja C, Shands WC, Blumgart LH. Carcinoma in choledochal cysts. Age-related incidence. *Arch Surg.* 1983; 118:986-988.
- Soreide K, Soreide JA. Bile duct cyst as precursor to biliary tract cancer. *Ann Surg Oncol.* 2007; 14:1200-1211.
- Jan YY, Chen HM, Chen MF. Malignancy in choledochal cysts. *Hepatogastroenterology.* 2000; 47: 337-340.
- Gidi AD, Gonzalez-Chavez MA, Villegas-Tovar E, Visag-Castillo V, Pantoja-Millan JP, Velez-Perez FM, Cano-Garcia F, Contreras AG. An unusual type of biliar cyst: A case report. *Ann Hepatol.* 2016; 15:788-794.
- Ohmoto K, Shimizu M, Iguchi Y, Yamamoto S, Murakami M, Tsunoda T. Solitary cystic dilatation of the intrahepatic bile duct. *J Clin Pathol.* 1997; 50:617-618.
- Dundas SE, Robinson-Bridgewater LA, Duncan ND. Antenatal diagnosis of a choledochal cyst. Case management and literature review. *West Indian Med J.* 2002; 51: 184-187.

Received April 26, 2023; Revised August 10, 2023; Accepted August 25, 2023.

[§]These authors contributed equally to this work.

*Address correspondence to:

Shizhong Yang, Hepatopancreatobiliary Center, Beijing Tsinghua Changgung Hospital, Tsinghua University. No.168 Litang Road, Changping District, Beijing 102218, China. E-mail: ysza02008@btch.edu.cn

Released online in J-STAGE as advance publication August 30, 2023.